

# WEIGHT LOSS E-NEWSLETTER

March 11, 2009

The information contained in this newsletter is for informational purposes only. It is not to replace the medical opinion rendered by a physician specifically to a patient.

Ara Keshishian, MD, FACS  
Dawn R. Keshishian, RN, CCRN

## Normal Bone Anatomy and physiology

Used with permission:

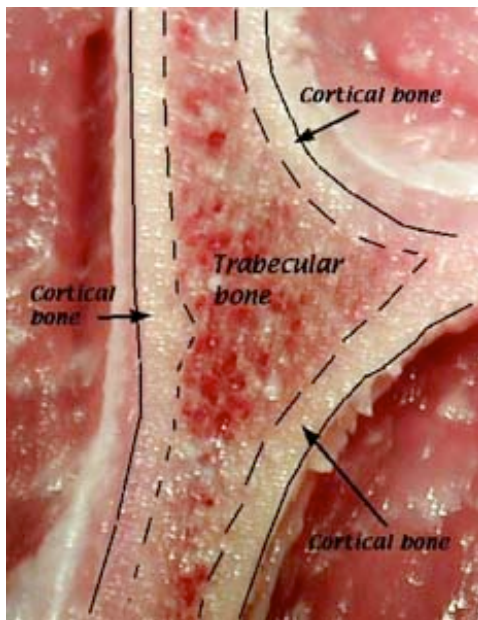
Susan M. Ott, MD  
Associate Professor,  
Medicine  
University of Washington

The bones in the skeleton are not all solid. The outside **cortical bone** is solid bone with only a few small canals. The insides of the bone contain **trabecular bone** which is like scaffolding or a honey-comb. The spaces between the bone are

filled with fluid bone marrow cells, which make the blood, and some fat cells.

You can see the difference yourself at the grocery store meat department. Here is a photograph of a T-bone steak

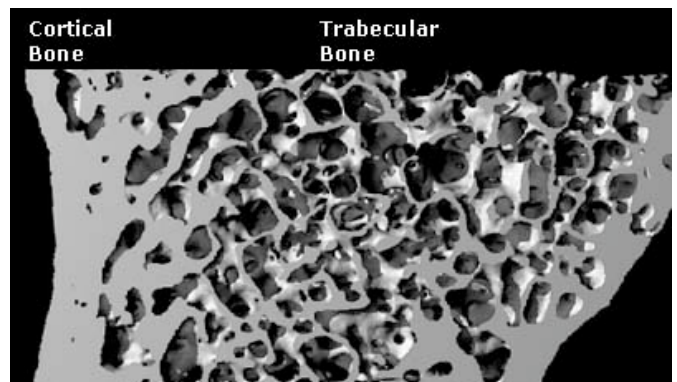
Below is a close-up picture of a piece of the pelvic bone. It was put into a special kind of xray machine which gives lots of details. The photograph is used with permission from Dr. Yebin Jiang from University of California, San Francisco.



If all the bones were solid, think how heavy they would be.

It would be hard to run!

The next page is about the cells inside the bones.



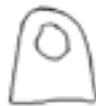# The cells found in bone

There are three special types of cells that are found only in the bone.

These cell names all start with "OSTEO" because that is the Greek word for bone.



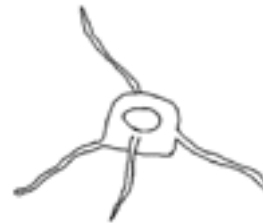**OSTEOCLASTS** are large cells that dissolve the bone. They come from the bone marrow and are related to white blood cells. They are formed from two or more cells that fuse together, so the osteoclasts usually have more than one nucleus. They are found on the surface of the bone mineral next to the dissolving bone.



**OSTEOBLASTS** are the cells that form new bone. They also come from the bone marrow and are related to structural cells. They have only one nucleus. Osteoblasts work in teams to build bone. They produce new bone called "osteoid" which is made of bone collagen and other protein. Then they control calcium and mineral deposition. They are found on the surface of the new bone.



When the team of osteoblasts has finished filling in a cavity, the cells become flat and look like pancakes. They line the surface of the bone. These old osteoblasts are also called **LINING CELLS**. They regulate passage of calcium into and out of the bone, and they respond to hormones by making special proteins that activate the osteoclasts.



**OSTEOCYTES** are cells inside the bone. They also come from osteoblasts. Some of the osteoblasts turn into osteocytes while the new bone is being formed, and the osteocytes then get surrounded by new bone. They are not isolated, however, because they send out long branches that connect to the other osteocytes. These cells can sense pressures or cracks in the bone and help to direct where osteoclasts will dissolve the bone.

